

A study in structural dynamics

MARVIN SOLIT, A.B., D.O., Brookline, Massachusetts

The object of this paper is to define and formulate a concept of normal body mechanics and to introduce a manipulative technique that will bring individual bodies toward this norm.

What is "normal" ?

To properly understand and employ this "normalizing" technique it is essential first to sharply define the term "normal." I feel that the failure to discriminate between "average" and "normal" has been a major stumbling block in the progress of the healing arts.

As students in our first years of medical school, we were taught so-called normal anatomy, normal physiology, normal body mechanics, and so forth. We examined and experimented on fellow students who were generally assumed to be normal. This was based on the assumption that only with a knowledge of the normal can the abnormal be diagnosed and treated. Although the principle is sound, it was not brought to our attention that what we were labeling "normal" was, at best, a "better than average."

There are two basic weaknesses in the conventional approach to determining "normal." First, the criteria for acceptance in the normal test group are vaguely or arbitrarily defined. In actual practice, the absence of disease and/or symptoms (at least

in the particular area under study) is the prerequisite for acceptance in the normal group. This is difficult if not impossible to measure. Second, the final results of the testing are reduced to statistical averages which fail to recognize the uniqueness of the individual.

Admittedly, this present technique has been well accepted and is useful; nevertheless, there exists today a confused picture of exactly what is normal. Thumbing through medical literature, one finds wide disagreement among different authorities in almost every area of research.

For example, in the study of body mechanics and kinesiology . one can find recognized authorities supporting *all* of the following points of view:

1. In normal standing the feet should be (a) toed out at a 30-degree angle,¹ (b) parallel,²
2. A perpendicular line through the center of gravity should fall in the midline (a) between the ball and heel,³ (b) 1 cm. anterior to the ankle joint,⁴ or (c) through the ankle joint.
3. Weight-bearing forces should be distributed predominantly (a) on the lateral aspect of the foot,⁵ or (b) on the medial aspect of the foot.
4. The spinal curves should be: (a) as shallow as possible, or (b) "One may accept as normal a higher degree of lordosis of the lumbar spine so long as it is compensated by a commensurate kyphosis of the dorsal spine, and so long as the line of gravity continues to intersect the spinal column at the conventional levels and so long as it still falls between hip and sacroiliac articulations."⁶
5. In regard to gross mechanics, some authorities distinguish attitudinal types of normal, such as re-

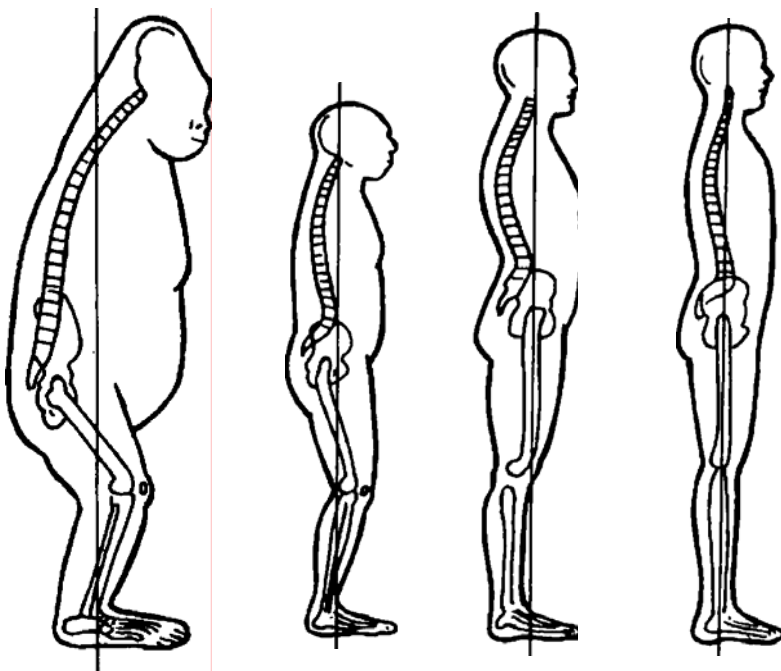


Fig.1. From left to right: (a) gorilla; (b) Neanderthal man; (c) average modern man; (d) normal modern man.

laxed normal and military normal,⁷ and body types such as mesomorphic, ectomorphic, and endomorphic normals.⁸

The problem of "what is normal" is recognized in many other aspects of medical research. For example, when computing normal values in laboratory chemical tests it is necessary to consider not only body type but also diet. Normals for total serum cholesterol in orientals, who subsist on fish, rice, and vegetables, is 120 to 160 mg. per 100 cc., which is a far cry from the accepted 200 to 250 mg. per 100 cc. for Europeans and North Americans, whose diets are richer in proteins and fats.

Happily, the confusion, disagreement, ambiguity, and semantic fuzziness that pervades medical literature is reduced when concepts can be expressed in physics and mathematics. It is for that reason that

I use a physical-mathematical framework for defining normal. Only two normals are differentiated:

1. Absolute normal—a theoretic human functioning that represents the most efficient usage of energy. It is essentially a physical-mathematical model of man which does not exist in nature.

2. Relative normal—a functioning that for each individual represents the most economical performance of his own body. In this definition one can investigate and determine individual rather than group norms. One can compare the individual, not to other individuals and groups, but to his own normal and his own efficiency potential.

One can refer to the most economical functioning of each body as normal, using the following five points as criteria:

1. Movement is performed with minimum work, that is, minimum energy expenditure.
2. Motion can be initiated in any direction with maximum ease and speed.
3. Movement can start with minimum preliminary adjustment of the body.
4. Structure is appropriate to the most adequate functional position of internal organs and the nervous system.
5. There is minimum "wear and tear" on the parts of the body.

(Points 1, 2, and 3 were suggested by M. Feldenkrais, in *Body and Mature Behaviour*⁹)

Physical evolutionary trends

In constructing this "normal" it must be acknowledged that our present bodily form has "proved" itself by its survival record. I feel that it would be practical to consider the trends in man's evolution and to examine the material uncovered by anthropologic studies. The trends through fossils, anthropoids (gibbon, gorilla, and so forth) to Heidelberg man, to Neanderthal, Cro-Magnon, and modern man, show certain general modifications which may be summarized as follows:

General stature. The trend has been from semi-erect to erect. This was partially accomplished by the spinal curve going from a large "C" curve anteriorly to a spine with three smaller alternating curves (Fig. 1, a, b, and c). A line passing vertically through the center of gravity has moved progressively back from the toes in the direction of the

heel. While the height has been increasing very gradually, the weight has remained relatively unchanged.

Skull. The long oval shape has become more spherical (brachycephalic), more gracile, lighter, and smoother. The base of the skull has changed from an almost vertical position to a horizontal position: The jaw bone is becoming smaller with fewer molars. The over-all capacity of the skull has not increased appreciably; thus the brain has not increased much in actual size, but probably has changed in the relative proportions of its areas.

Chest. The ribs have become gracile and lighter. The external muscles of respiration (serratus anterior and serratus posterior, pectoralis major and minor, and so forth) have a lesser role in respiration, while the intercostal and the diaphragmatic muscles play a greater part.

Shoulder and neck. The neck has become longer and less thick, with greater range of motion, and the shoulder lighter and less muscular; bony (clavicular) attachments to the frame of the body give greater motion and ease of use. The placement of the scapula is becoming more lateral.

Pelvis. The trend in the pelvis is for less anterior tilt. The outlet of the birth canal is slightly enlarged. The pelvis is becoming wider and shorter.

Internal organs. Although it is impossible to determine what alterations have occurred in the internal organs, it can be inferred from the body skeleton that the position of the organs has changed from an actual hanging from the spine (like clothes on a line) to a suspension of the organs closer to the backbone.

Thigh bone. The thigh bone has become longer and straighter, with more of an adduction position.

Bones of the leg. Both the tibia and fibula are becoming longer and straighter. The fibula is becoming less robust and playing a decreased role in weight-bearing. The tibial plateau is becoming less retroverted and more horizontal.

Bones of the feet. The heel bone is increasing in size progressively and pressing closer to the ground. The first metatarsal has become longer; it and the second, third, fourth, and fifth metatarsals are settling closer together, with less range of motion. The inner arch is becoming more prominent and is assuming more weight-bearing. The toes are shortening, with less motion (Fig. 2). The feet are going from a position of inversion to one of eversion.

These are the trends in general, but carrying these trends beyond a certain point requires compromises. For example, if the skull and brain capacity increase substantially, the organic structure will require a larger birth canal (to facilitate child-birth), and consequently a larger pelvis.

The so-called law of squares and cubes formulates what is observable in organic change; notably,

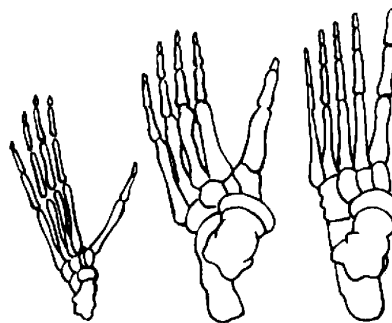


Fig. 2. From left to right: bones of gibbon, gorilla, and human feet.

that if the shape and proportions of any material body remain the same but the size varies, its strength increases as the square of any one dimension, while its weight increases as the cube. Accordingly, increasing the size of the pelvis, or any other bone, can conform with this formulation only through intricate compensations. For example, a heavier pelvis would require heavier thighs and legs; and if the height of the center of gravity is measured as a vertical distance along an axis from the bottom of the feet to the top of the head, this in turn would lower the center of gravity and increase the moment of inertia. But in order to satisfy points 1, 2, and 3 in the formulation of normality, the highest possible center of gravity and the lowest possible moment of inertia around the vertical axis would be desirable. With the highest possible center of gravity compatible with the structure, and the minimum moment of inertia, the body is poised at its maximum potential of energy level, and it can move in any direction with a minimum of energy expenditure.

Normal structural dynamics

The following description will be found to satisfy the requirements for normal, if normal is defined as "most economical functioning."

1. Viewing the body in profile, a vertical line through the center of gravity can be seen as falling through the major joints—ankle, knee, hip, and the atlanto-occipital junction. The three spinal curves (cervical, thoracic, and lumbar) should be minimal, but flexible throughout, and the spine will have no flat areas (Fig. 1, d).

2. The shoulder, consisting of the scapula and clavicle, functions independently of the chest wall, with the clavicle attached to the chest only at the breastbone and functioning only as a strut to keep the shoulder joint at its most lateral position.

3. The bones of the lower extremities—the tibia,

fibula, and foot bones—act as a unit, so that in standing and walking there is a maximum of translational motion (motion with minimal rotation of the parts) and the general direction of motion is in a plane parallel to the medial plane of the body.

4. The "weight" of the body is distributed as close to the vertical line going through the center of gravity as possible. An analysis of weight distribution on the feet would reveal that the calcaneous area supports the maximum weight, with the lateral longitudinal arch supporting practically no weight.

5. The position of the pelvis is as vertical as possible. A pelvis is considered vertical when a horizontal plane goes through the anterior and posterior spines of the ilium (Fig. 1, d).

6. As the arrangement of the bones assumes a more stable relationship with the "forces of gravity," there is a structural modification of the muscle-fascia units. The active contractile elements (actin, myosin, and so forth) become reduced in quantity, resulting in a relative increase in the fascial elements. The more balanced the body, the more it is supported by the antagonistic pull of the fascia.

(Using words like "muscle" and "fascia" as if they exist as separate entities creates a separation which does not exist clearly in nature. Medical students in their anatomy dissection can attest to this, as they find it extremely difficult to "clean" a lower extremity muscle. The fascia does not cleanly strip away from the muscle and bone, and the final separation depends to a large extent on the preconceived formulations of the dissector. The term "muscle-fascia" considered as a functional unit more accurately describes the situation.)

In considering the musculoskeletal system of this "normal" body, the following points are apparent:

1. There is a greater opportunity for "independence" of action by the major parts of the body, such as head and neck, chest, shoulders, pelvis, and lower extremities. For example, the movements of the head and neck can operate without necessarily involving gross movement of the chest or shoulders. The shoulders and arms can function without involving the chest. The pelvis can rotate and twist without disturbing the parts above it. The rib cage has been freed to function mainly for respiration and need not be involved in the tasks of other parts of the body. Elevation of the emancipated ribs (in inspiration) can easily be accomplished by the contraction of the intercostal muscles, and expiration achieved by a simple relaxation of the intercostals, allowing gravity to do the work.

2. The tendency toward specialization of parts is exemplified by the development of the nervous system. The central nervous system and the brain, together with the bony spine and cranium and the muscles of the spine (suboccipital, interspinales, rotatores, and multifidus), can be considered as a complete and integrated unit. This unit occupies

the area of the body which can be considered the longitudinal core—the area least affected by gravity—and it is to a degree functionally independent of the rest of the body. This unit is now structurally best able to perform its functions.

3. This musculoskeletal arrangement allows the heart and other viscera to be suspended close to the spine, rather than to have an anterior and inferior sag.

Recalling that the specifications for the "normal" body involved considerations of movement, energy expenditure, and the like, one must test the normal body, not in a static standing position, but in movement. Locomotion, one of the body's most important acts, should be a good test.

Starting from a standing position with the body at its maximum height and highest center of gravity (maximum potential energy), movement is initiated by the forward movement of the head. Practically simultaneously, the movement is followed by the long extensor muscles of the back (sacrospinalis) stretching and lengthening as the psoas and iliacus contract and easily swing the femur and consequently the entire extremity forward. The foot skims along the ground with the heel rising very slightly to help maintain the body at its maximum height. (This action of the sacrospinalis, psoas, iliacus, and corresponding fasciae allows the lumbar curve to straighten and the pelvis to extend, which also lengthens the body.)

The entire extremity moves directly forward with a minimum of rotation of the parts. Traces left by the feet are parallel and reveal a narrow base. The lateral weight of the body is close to the medial plane in every part of the walking cycle; so transfer of weight to the opposite side requires minima/ muscular activity, and is also accomplished primarily through the utilization of "gravity." The head, chest, and pelvis, during the walking cycle, sustain minimum vertical movement and maximum translational horizontal movement.

To answer a reader who may feel that this way of walking is too simple to really work, I cite the work done with artificial limbs. Experience with artificial lower limbs tends to substantiate the simplicity of walking, for these prostheses of wood and metal have no arrangement for muscles (other than for the stump of the thigh which fits into the hollow of the prosthesis), and the ankle and knee are simply hinge joints—yet these devices work very efficiently as a substitute for the more complicated human extremity.

We see that "normal" walking requires a minimum of work and consequently a minimum of energy expenditure. Motion is accomplished with maximum ease and can be initiated with a minimum of previous adjustment of the body. The internal organs are in their best functioning position at all

times, and there is the least possible wear and tear on the body as a whole.

There are at present numerous methods for measuring body movements. Most of the standard techniques involve photography. I am personally familiar with the multiple image technique used by Dr. Franklin Pierce Jones¹⁰ and his associates at the Institute for Applied Experimental Psychology at Tufts University. With this technique the subject is dressed in dark clothing, and white strips are attached in strategic areas indicating the zygomatic arch, the seventh cervical vertebra, the sternal notch, the lateral aspects of the arm, forearm, thigh, and leg, and the sole of the shoe. The subject walks along a ramp in a darkened room and the pattern of movements is recorded on a color film by the Strobolume flashing at 10 fps and coded by a color wheel revolving in synchrony.

This method is useful because it gives a record of the motion of all the parts simultaneously, but the detailed measurements and calculations, such as velocities and accelerations, are painfully laborious and time-consuming.

Locally, Northeastern University's Department of Mechanical Engineering has been experimenting with a more recent technique using small accelerometers attached to different areas of the body.¹¹ The accelerometers can give rapid, accurate direct measurements of acceleration, velocity, and displacements. This technique has the disadvantage of requiring the attachment of the equipment to the subject, which in itself slightly modifies the motion pattern. Ideally, a technique should not restrict the subject in any way, and should at the same time compute and reduce data with a minimum of effort.

Treatment by Postural Release

Consideration of the "normal" which I have outlined suggests the need for a practical therapy which will bring individual bodies closer to these norms. The technique which I have found most effective in achieving this end is the manipulative system devised by I. P. Rolf,¹² which is called Postural Release. To give the reader an understanding of the principles and procedures involved in Postural Release, I will describe in detail the "processing" of a specific patient, from the initial evaluation to the final treatment, including appropriate comments on this therapy in general, which may help to clarify certain points.

Case 1 • The chief complaints of this 38-year-old woman were;

1. Low-back pain, with an onset 6 years ago, progressively increasing in severity. X-rays taken the previous year showed evidence of lower lumbar osteoarthritis.

2. Stiffness of neck and "tight shoulders" associated with suboccipital headaches.

3. Shortness of breath particularly noticeable when participating in activities which previously were not a strain.

4. Pain under the metatarsal area of left foot and frequent cramping of calf muscles of the right leg.

The physical examination showed that her weight was 149 pounds (there had been no change in the past 10 years) and her height was 5 feet 6 inches. Heart and lungs were essentially negative. The blood pressure was 108/60, and pulse rate was 76.

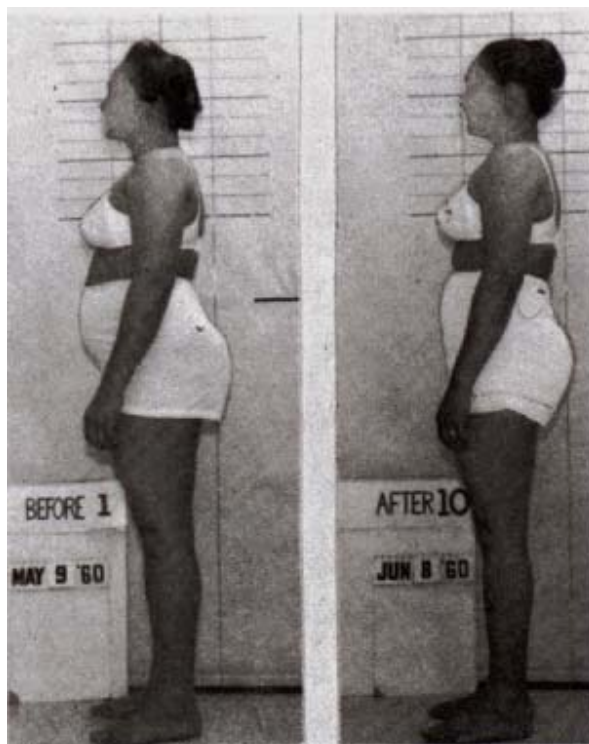

Fig. 3 (Case 1)

Gross structural evaluation (Fig. 3, left) showed anterior pelvic tilt, lordosis, depressed chest, bilateral hammer toes, and hallux valgus grade II. It is interesting to note that although the patient was not obese, she had areas of marked disproportion, namely the gluteal area, abdomen, and thighs. The range of motion of all joints was limited. The patient was a belly breather and her costal respiratory movements were markedly restricted.

A photographic record was made. For this purpose, I routinely used a 35 mm. Retina reflex camera and a Polaroid Land camera, taking front, back, and lateral views at a distance of 10 feet. Patients are asked to stand comfortably and in a relaxed posture for all pictures. The 35 mm. camera is best for detailed examination and for making enlargements

and slides. The 10-second Land camera serves to give the patient an immediate appreciation of his problem and an understanding of what is involved in straightening it out. In addition, the postural changes occur rapidly during treatment, and these changes can be readily seen in the pictures taken before and after each treatment.

It was apparent that this patient was operating far below her level of maximum efficiency. Recalling the criteria for normal, the respective centers of gravity of the gravitationally significant parts of the body—head, chest, pelvis, and lower limbs—should fall in the line of gravity; when this happens the entire system is in equilibrium. The translatory and rotary components of the gravity forces are negligible.

The centers of gravity of the significant parts of this patient's body did not fall in the line of gravity, and the disorganizing tendencies of the gravitational forces had to be equalized by other forces, namely the myofascial elements of the body. The myofascial elements, which in the normal body are used mainly for body motion, would now be required to take on the additional job of body support. It should not be surprising that a closer examination of this patient revealed that these compensating structures and muscles, including their tendons, fascial sheaths, and ligaments, were shortened, thickened, rigid, displaced and inelastic. The normal muscles should slide easily in their fascial sheaths while shortening and lengthening, much as a piston moves in its well-oiled cylinder. The patient's body could be likened to a "muscle machine" that was not "hitting" on all its cylinders. It sorely needed a tuning, cleaning, and lubrication. To quote A. T. Still, "The fascia is the place to look for the cause of disease, the place to consult and begin the action of remedies in all diseases even though it be the birth of the child."¹³

In describing the actual treatment, descriptive words such as "corrective movement," "normalization," and "manipulation" are used. It is implied that the therapist has examined the area under consideration both visually and by direct palpation to determine the precise area of restricted movement and tight, strained, displaced myofasciae. These areas feel knotty, hard, and even gristly, and are tender to the touch.

When a joint is grossly put through its range of motion the specific trouble areas will demonstrate maximum limited motion. Muscles and tendons in these areas feel "bunched up," and deep palpation reveals a lack of differentiation of structure. The subtle individual movements that characterize a well-working normal area are diminished or absent.

Once these areas are located and evaluated, the therapist, using his fingers, clenched fist, forearm, or even elbow at times (depending on the degree and type of force necessary), exerts pressures in specific directions until these areas show signs of changeless ropiness, appropriate lengthening, and so forth.

Repeating the joint movements will then show increased ease of motion.

The patient's individual treatment program consisted of a series of ten manipulative "processings." Each processing was of approximately 1 hour's duration, and each one was a definite step toward recreating in the body a more normal pattern of movement and posture.

1. The immediate goal of treatment one was the improvement of respiratory movements to help increase general tissue oxygenation. This facilitated the rest of the tissue responses to manipulation. The patient's chest was restricted by the shortened, tightened auxiliary muscles of respiration, specifically the pectoralis major and minor and the serratus anterior. The abdominal muscles, as they attach to the lower ribs and sternum, were also involved. After working on these areas there was an immediate increase in the respiratory rib movements. The patient noticed an immediate ease and freedom in her breathing.

The remainder of the treatment was concerned with increasing the mobility of the pelvis to enable it to function more independently of the chest above and the limbs below. This necessitated manipulation of the muscles around the hip joint, especially the gluteals and tensor fasciae latae. This procedure, plus lengthening the rectus femoris, allowed the pelvis to decrease its anterior tilt. The patient could feel that her sway back was flattening out.

2. The goal of the first 2 hours was the mobilization of all the superficial fasciae and muscles. The superficial fascia is the bridge connecting the corium layer of the skin to the deep fascia. This bridge must be crossed manually to reach the deeper structures.

During the second hour's treatment the feet and legs were worked on first. The patient's "hammer toe" condition was the result of her using her toes as a support to prevent her anteriorly imbalanced body from falling further forward. The extensor hallucis longus and the extensor digitorum longus and brevis, as well as the calf muscles and plantar fasciae, were involved with body support, and were strained, shortened, and even fibrotic. After working on these areas, in addition to generally reducing the anterior body tilting, the patient stated that her feet felt lighter and less tender.

In general, I have found that in the manipulative correction of gross body mechanics, foot problems such as hallus valgus, hammer toes, calluses, metatarsalgia, and flat feet can be significantly improved to the point where special shoes and orthopedic appliances are no longer necessary. This has been especially gratifying, for many of the orthopedic

appliances and devices that are designed to improve a local area do so by redistributing body strains rather than by correcting them. For example, a foot plate or inner sole wedge may decrease the symptoms for which it is prescribed, but in terms of gross body mechanics it essentially lateralizes the weight distribution and creates a less efficient and more strained body. It is not generally appreciated that the readjustment of one area may be the direct cause of trouble in a distant area of the body at a later time.

3. As the patient put her shoulder joint through its range of motion, there was markedly restricted movement of the entire shoulder girdle. The scapula and clavicle acted as though they were tied down to the chest wall. The areas of restriction involved the rhomboids, teres, and latissimus dorsi muscles. As these areas were worked on, the stiff shoulders noted at the patient's initial examination became less stiff.

The lower back muscles, especially those attaching around the crest of the ilium, were very rigid, particularly the quadratus lumborum. The lumbar vertebrae were not only individually in lesion, but the entire lumbar spine was jammed together. It behaved like one solid block of bone, rather than as individual vertebrae capable of independent motion. The ability of the spine to lengthen during activity, which is a fundamental characteristic of normal spinal mechanics, was absent. Working on the above-mentioned muscles and the sacral spinalis group improved the gross spinal motion. The low-back pain, which had diminished after the second hour's treatment, significantly subsided after this hour's processing.

4. The fourth hour's processing involved lengthening and balancing the adductors of the lower limbs. The adductor magnus, brevis, minimus, and the gracilis and pectineus originate on the ischio-pubic ramus and are inserted on the linea aspera of

the femur. It is necessary to lengthen these muscles in order to decrease the anterior pelvic tilt and restore pelvic balance.

5. The detailed description of the normal body mentioned that there should be an independence of motion of the pelvis and chest. Looking at the patient at this time, this motion seemed to be prevented by the abdominal muscles.

As one looks at a patient's protruding abdomen, one might think that the abdominal muscles were weak, and that the treatment should be geared toward strengthening them. By palpating the abdomen, however, one would not feel the flabby, atonic muscles which would be the evidence of weakness; rather, the muscles are tight, bunched, and shortened. This should not be surprising, because here again is an example of muscles working overtime, maintaining body equilibrium. In addition, these muscles are supporting the sagging viscera, which normally would be supported by their individual ligaments. As the abdominal muscles are freed and lengthened, there is a general elevation of the rib cage, which in turn elevates the head and neck. It is customary to hear patients say, at the end of this hour, that their necks feel less strained and it is easier to stand tall.

The ramifications of the experience gained from freeing the belly walls carry over into the field of physical education. With the recent emphasis on "health through physical fitness" programs, millions of people are undertaking physical fitness regimens. The majority of exercises in these regimens are designed to tighten and strengthen the abdominal muscles. During the past 3 years I have conducted calisthenic and posture classes at the Boston YMCA, and I have had an opportunity to study many people who have been practicing abdominal strengthening exercises. While it was evident that they were hardening the abdominal wall, it was also evident that many of them were not successful in reducing their "pots," and almost all of them had succeeded in pulling down their chests.

The explanation for this relates directly to the anatomy and kinesiology of the abdominal muscles. These muscles are attached to the chest above and to the pelvis below. The direction of pull of any muscle depends on the relative degree of fixation of the bony muscular attachments. As the pelvis is the more immobile end of the muscle, and the ribs the relatively unfixed end, a shortening and tightening of the abdominal muscles will pull the ribs down.

In this patient's "after" photographs (as well as in those of the rest of the cases), it is evident that the bellies become less prominent when "processed." These changes are produced without weight losses or muscle-strengthening exercises.

B. This hour involved the organization and integration of the muscles of the lower limbs, balancing

There are two basic weaknesses in the conventional approach to determining "normal." First, the criteria for acceptance in the normal test group are vaguely or arbitrarily defined. Second, final results of testing are reduced to statistical averages which fail to recognize the uniqueness of the individual

the rectus femoris muscles with the extensors (the hamstring muscles), balancing the anterior tibial muscles with the posterior tibials, and balancing the adductors with the abductors.

These muscle groups are considered to be integrated and balanced when contraction of one set of muscles results in the instantaneous lengthening of its antagonist muscles, and vice versa.

It is at the completion of this hour's treatment that there is significant improvement in such conditions as pronated and everted feet and bowed and knocked knees.

I am continually impressed with the fact that these are not just foot or knee problems, but involve correction of over-all body mechanics. For example, pronated, everted feet are usually associated concomitantly with an anterior pelvic tilt; lumbar lordosis often accompanies internally rotated tibiae.

7. It was apparent at this time that the patient's head and neck were still too far forward. The neck muscles, especially the anterior muscles—scaleni, sternocleidomastoid, and strap muscles—were shortened. The posterior neck muscles, including the semispinalis capitis, splenius capitis, trapezius, and suboccipital muscles, took on the role of preventing the imbalanced head and neck from falling forward. As a result, these muscles became overly tightened, restricting neck motion further.

The manipulation of the myofasciae of the neck is especially important, as these fascial planes are the "highways" for the many arteries, veins, and nerves in this area. The deep fasciae which originate on the basocranium, superior nuchal line, and mandible, surround all the muscles, arteries, veins, and nerves of the neck, and continue to the mediastinal partition, the pericardial envelope, and the central tendon of the diaphragm.

The patient's suboccipital headaches, shortness of breath, and neck and shoulder stiffness showed considerable improvement after this hour's treatment.

8 and 9. These two treatments involved processing the same areas of the body as the third and fifth hours, with this exception: With the improvement of the superficial layers, I could now reach the deep myofascial layers.

For example, the lumbar lordosis and anterior pelvic tilt to a large extent were being held in their mechanically compromised positions as a result of the pulling and shortening of the psoas and iliacus muscles. Lengthening these muscles through the anterior belly wall significantly improved the pelvic and lumbar vertebral mechanics.

It was interesting at this point to see the patient's ill-proportioned hips assume a more desirable contour. For the first time in her life the patient was now aware that her figure problem was not a problem in weight, but rather of posture and balance.

10. The final treatment involved a general over-all

balancing of the body. Special attention was paid to freeing up the entire length of the spine to the point where the spine was flexible and could lengthen from the first cervical to the fifth lumbar. Flexion of the neck should produce a wave of motion that travels uninterruptedly down the spine to the sacrum.

As it is generally acknowledged that "disk" lesions are largely the result of disk compression, the attainment of the tenth-hour goal is a significant step in both the prevention and treatment of disk disease.

The "after" picture (Fig. 3, right) shows graphically the final result of the therapy. The patient felt as well as she looked, and except for an occasional headache, was asymptomatic. Routine rechecks 6 months later and 2 years later showed that the patient was continuing to enjoy good health. The original blood pressure of 108/60 climbed to 118/78 and remained in that general range. The weight remained constant at 149 pounds.

Case 2 • A 15-year-old girl had chief complaints of (1) postprandial epigastric pain, nausea, and vomiting, relieved by lying down (gastrointestinal x-ray study at the Massachusetts Osteopathic Hospital showed delayed emptying time, probably due to external pressure on the duodenum) ; and (2) frequent "colds" in the neck, and neck stiffness.

Physical examination showed an ectomorphic type build with lordokyphosis, genu recurvatum, pronated and everted feet, and visceroptosis (Fig. 4).

The diagnosis was mesenteric drag syndrome (arteriomesenteric occlusion), with poor body mechanics, especially visceroptosis and lordosis. The intermittent type of duodenal obstruction was considered to be caused by compression of the third portion of the duodenum between the root of the small bowel mesentery and the lumbar spine. The patient did not respond to the conventional medical regimen of dietary changes and drugs.

The patient received 10 hours of myofascial proc-

In constructing the "normal" it must be acknowledged that our present bodily form has "proved" itself by its survival record. The trend in man's evolution has been from semierect to erect. A line passing vertically through the center of gravity has moved progressively back from the toes in the direction of the heel

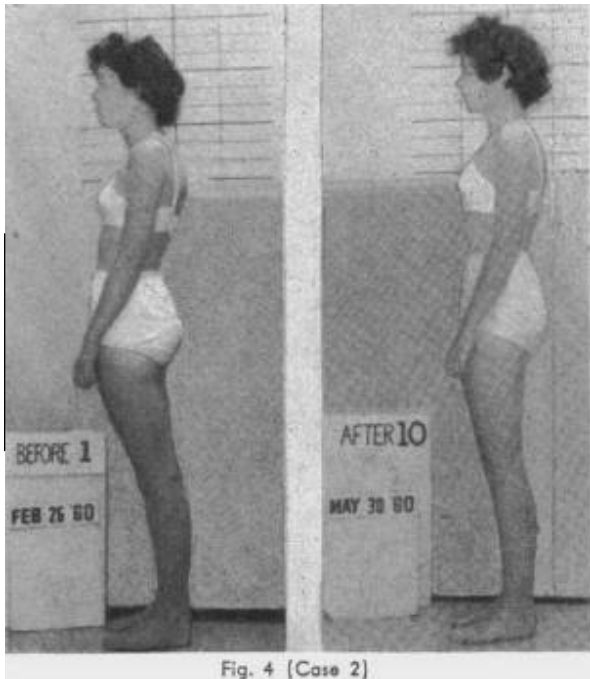


Fig. 4 (Case 2)

essing between February 27 and May 20, 1960. Her symptoms subsided and she had no recurrence.

The most interesting aspect of this patient's treatment was the emotional abreaction she had while I worked on her rigid, even spastic, abdominal wall. This child came from an extremely stern, rigid home and she attended a strict parochial school. Even when she laughed, one could see that her laugh mechanism was indrawn rather than expansive, and thus was not a form of release. In addition to the subsidence of her gastrointestinal symptoms, there was a significant personality improvement, as noted by her parents and teachers.

Case 3 • A 20-year-old man (Fig. 5) had chief complaints of (1) pain in the right side of the chest, and (2) loss of weight and night sweats.

He was admitted to Boston City Hospital on May 19, 1959, with a positive culture for tubercle bacillus. An x-ray study showed increased pleural density in the right lower chest. The diagnosis was tuberculous pleurisy with effusion. The treatment was para-aminosalicylic acid, 600 mg., and isoniazid, 24 grains daily. From May 19 to September 26, 1959, there was no objective or subjective change.

On October 13, 1959, the patient joined the author's calisthenic posture class at the Boston YMCA. Within 3 weeks his chest felt easier and he stopped the medication. An increased dosage had been making him nauseous, and the patient felt that it was not helping him.

On November 15, 1959, the patient started postural release treatments. X-ray examination on

February 2, 1960, at Boston City Hospital showed resolving of pleural fluid levels.

The patient completed his myofascial processing on March 10, 1960, and at that time reported no objective or subjective symptoms. Re-examination 6 months later (Fig. 5, right) found the patient feeling well and having gained 10 pounds. X-ray examination on January 18, 1961, showed normal pleural density and a tent adhesion of right diaphragm.

This case reaffirms in my own mind the osteopathic understanding that there is more to the treatment of the infectious diseases than trying to destroy the germs (the so-called causes) with antibiotics.

Case 4 • The case of an osteopathic physician, aged 60, is worth describing although there was no serious "chief complaint," except for an occasional dull ache in the lower back. This man, although asymptomatic, recognized the importance of structural integrity and understood that he could undergo therapy as a preventive measure.

From the accepted medical evaluation this patient would be considered "normal." However, from the definition of normal outlined in this paper, it was apparent that he was functioning far below his potential ability (Fig. 6, left). As he approached his normal (Fig. 6, right), he reported that he was feeling less fatigued and in general felt more energetic and alert. His only "complaint" concerning the therapy was that he had had to have his suits altered.

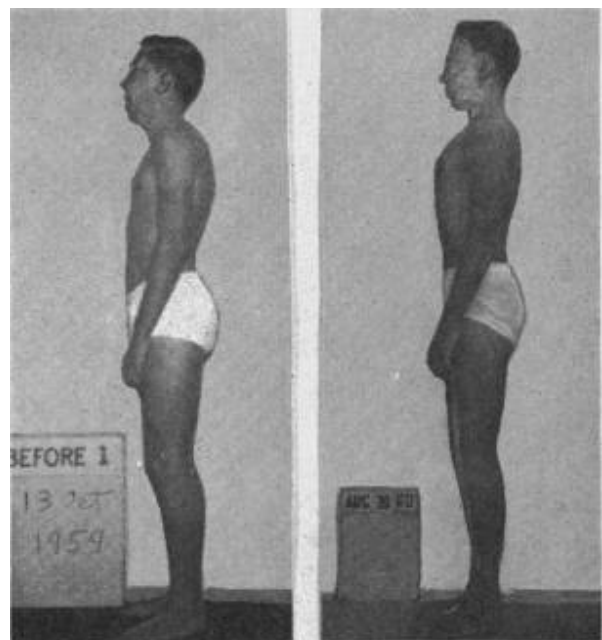


Fig. 5 (Case 3)

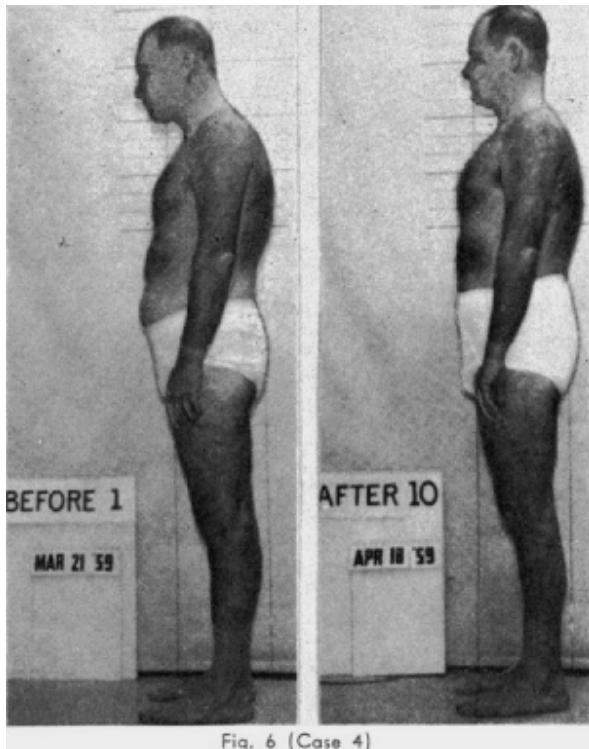


Fig. 6 (Case 4)

Case 5 • A 68-year-old man had numerous complaints, involving practically every system in his body: (1) recurrent shoulder and low-back pain; (2) generalized joint stiffness; (3) low-back pain radiating into anterior lateral aspect of the right leg, below the knee; (4) exertional dyspnea; (5) nocturnal urinary frequency; (6) diminished hearing; and (7) occasional heart "flip-flops" (to quote the patient).

The diagnoses were: (1) generalized myof-ibrosis; (2) lumbar arthritis (x-ray showed lumbar facet joint arthrosis and spondylosis) ; (3) fifth lumbar nerve root irritation (x-ray showed that the disk between the fourth and fifth lumbar vertebrae was narrowed) ; (4) bilateral shoulder bursitis (x-ray showed extensive tendinitis calcarea) ; (5) premature extrasystole and generalized arteriosclerosis; (6) tympanic membrane sclerosis; and (7) benign prostatic hypertrophy (the patient had been under care at the Lahey Clinic where surgical treatment of this condition had been suggested).

Between August 1. and October 18, 1958 the patient underwent 10 hours of myofascial therapy. He experienced improvement of his generalized stiffness and shoulder and back pain. The nerve root pain subsided but areas of hyperesthesia persisted. The patient stated he felt less fatigued and had 1:0 difficulty breathing in exertion. In addition to the physical improvement, there were marked changes in his attitude toward his body. He recognized that his symptoms and conditions were not just

due to "old age," and he did not have to "learn to live with them."

He was placed on a high protein, low carbohydrate diet and a comprehensive supplemental nutritional regimen. Also, he was given a series of special calisthenic exercises designed to further improve his body balance and usage.

When the patient was seen a year later he felt and looked even better and his areas of hyperesthesia had disappeared. On January 5, 1959, he had undergone operation at the Lahey Clinic for a solitary thyroid nodule, which was found to be benign. He also had had two episodes of bursitis, which subsided easily. The patient underwent a second series of treatments from September 3 to November 1, 1959.

During 1961 the patient, then 71 years old, was feeling well and pain-free, and his urinary symptoms subsided. At a recent Lahey Clinic check-up for his prostatic condition, the patient was told that the area was now normal and required no treatment at present.

Discussion

In a recent article, "Osteopathy and Medical Evolution," Irwin M. Korr¹⁴ reminds us that medicine is a pervasive part and product of human culture and, like all other major endeavors and sociocultural phenomena, is in a continual process of evolution. With his thorough knowledge of both the strong

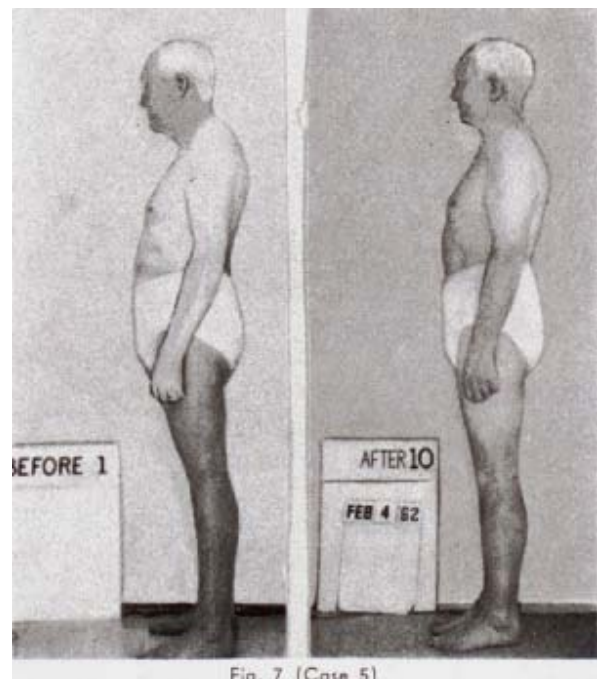


Fig. 7 (Case 5)

points and weaknesses of present-day medical philosophy and techniques, he discusses what will be what has to be the next higher stage of medicine.

To paraphrase him, we will be engaged much less in intervening in the inconceivably complex biologic processes of the human organism than in creating circumstances in and around the individual that will permit his optimal operation and in eliminating impediments to his operation. We will be directing efforts less toward specific causes of diseases and more at the factors that permit them to become causes. We will recognize that the musculoskeletal system of the body is the most massive system, the main instrument of activity, the framework of the circulatory and nervous systems, and the largest consumer of material and energy. Improvement in the health of a person must be influenced by improvement in this system. We will be concerned in practice with helping the individual patient make the best possible adaptation to the environmental factor that makes the most severely exacting demands on him—namely, gravity.

I would further add my belief that engineering, a physical-mathematical science, will dominate medical research and philosophy. Even in the past 20 years, men doing research in fields such as biophysics, biomechanics, and biomathematics, in such engineering schools as the Massachusetts Institute of Technology and the California Institute of Technology, have been making contributions and even giving direction to medical progress.

As osteopathic physicians we share the same basic premise as the biologic engineers, that the human body is a machine. A. T. Still frequently asserted, "An osteopath is only a human engineer who shall understand all the laws governing his engine, and thereby master disease."¹⁵

The future developments of medical engineering will promote, enhance, verify, and validate the osteopathic concept, if we translate our private osteopathic terminology into the general language of engineering, and if we can demonstrate that manipulation of the body can produce a more efficient machine.

I hope that the two main points introduced in this paper, (1) a physical-mathematical concept of "normal," and (2) a manipulative technique, "Postural Release," for achieving this normal, can serve as steps in this direction.

Summary

As physicians we often use the word "normal," as normal physical findings, normal blood chemistry, normal body mechanics, and so forth. It is rarely pointed out that what *we* are labeling and accepting as normal is at best a "better than average."

Even though present techniques for establishing normals are useful and well accepted, they are nevertheless vague and arbitrary. It is my feeling that the failure to discriminate between "average" and "normal" has been a major stumbling block in the progress of the healing arts.

The confusion, disagreement, and semantic fuzziness that pervades medical literature is reduced in physics, mathematics, and engineering. For this reason I propose a physical-mathematical formulation of "normal" for the body of man. "Normal" in this paper refers to the most economical functioning of the human body.

After describing a body design that is capable of performing most economically, a myofascial manipulative technique has been introduced, which I use to bring patients toward their potential norms and hence toward optimal body functioning.

Five cases of patients who have undergone this myofascial therapy have been presented, including postural pictures before and after therapy.

1. Morton, D. J.: *Human locomotion and body form*. Williams & Wilkins Co., Baltimore, 1952.
2. Kendall, H. O., Kendall, F. P., and Boynton, D. A.: *Posture and pain*, Williams & Wilkins Co., Baltimore, 1952.
3. Steindler, A.: *Kinesiology of human body under normal and pathological conditions*. Charles C Thomas, Springfield, Ill., 1955.
4. Lovett, R. W.: *Lateral curvature of spine and round shoulders*, Ed. S. P. Blakiston's Son & Co., Philadelphia, 1931.
5. Jones, L.: *Postural complex; observations as to cause, diagnosis and treatment*. Charles C Thomas, Springfield, Ill., 1955.
6. Steindler, A.: *Op. cit.*, ref. 3, p. 228.
7. Braune, W., and Fischer, O.: *Ober den Schwerpunkt des Menschlichen Körpers*, vol. XV. *Abb. Math. Phys. Klass. Kgl. Sachs. Ges. d. Wiss.* 20 VII, S. Hirzel, Leipzig, 1889.
8. Goldthwait, J., et al.: *Essentials of body mechanics*. Ed. 5. J. B. Lippincott Co., Philadelphia, 1952.
9. Feldenkrais, M.: *Body and mature behaviour*. International Universities Press, New York, 1949, p. 75.
10. Jones, F. P., et al.: *Experimental study of effect of head balance on patterns of posture and movement in man*. *J. Psychology* 47:247-258, 1959.
11. Yorra, A. J., Monks, D. K., and Solit, M.: *Unpublished report, Northeastern University Department of Mechanical Engineering*, Nov. 1960.
12. Rolf, I. P.: *Postural Release*. Published by author, 1.1 Riverside Drive, New York, 1957.
13. Truhlar, R. E.: *Doctor A. T. Still in living*. Published by author, 31437 Shaker Blvd., Chagrin Falls, Ohio, 1950, p. 54.
14. Korr, I. M.: *osteopathy and medical evolution*. *J. Ans. Osteop. A.* 61:515-526, March 1962.
15. Truhlar, R. E.: *Op. cit.*, ref. 13, p. 41.